

Case report

Urinary steroid metabolites in a case of florid Ectopic Cushing's syndrome and clinical correlations

Angelos Kyriacou,¹ Karolina M. Stepień,² Basil Issa¹

¹Department of Endocrinology & Diabetes, ²Department of Clinical Biochemistry, University Hospital of South Manchester (UHSM), Manchester, UK

ABSTRACT

A 51-year old woman was admitted with multiple cerebral, pulmonary and intra-abdominal abscesses. The combination of apparent immunosuppression, obesity, diabetes mellitus, hypertension, hypokalaemia, osteoporotic fractures and bilateral shoulder avascular necrosis led to a clinical diagnosis of Cushing's syndrome (CS). This was biochemically confirmed as follows: midnight serum cortisol 4275 nmol/L (60-250), non-suppressed overnight dexamethasone suppression test, raised salivary cortisol 716 nmol/L (5-46) and ACTH 639 ng/L (0-46). Urinary free cortisol was elevated >75,000 nmol/L (<165). Urinary steroid metabolites measured by Gas Chromatography Mass Spectrometry were markedly increased: tetrahydrocortisol (THF) 219024 µg/24h and tetrahydrocortisone (THE) 88848 µg/24h. The (THF+5αTHF)/THE ratio was 2.8 (≤1). Pituitary MRI was unremarkable and whole body CT scanning showed a thymic tumour and bilateral adrenal hyperplasia. Urinary 5HIAA was marginally raised with a normal chromogranin A. She underwent a thymectomy which confirmed a 'paraganglioid' variant of a thymic carcinoid tumour. We describe a case of ACTH-secreting thymic carcinoid that presented with florid clinical and biochemical features of CS, but no carcinoid syndrome. The (THF+5αTHF)/THE ratio is reported to be a useful indicator in differentiating the aetiologies of CS, although this was not the case in our patient. In this article we examine the degree to which the various urinary steroid metabolites were raised in this patient with florid CS and compare them with some normative data obtained from patients with either Cushing's disease or the normal population. We hereby postulate that steroid metabolomics profiling may be helpful in establishing the differential diagnosis of CS.

Key words: Thymic carcinoid, Cushing's syndrome, ACTH, Urinary glucocorticoid metabolites

INTRODUCTION

Neuroendocrine tumours (NET) are rare tumours

with an incidence of 3.24 and 4.44 per 100,000 persons per year in Norway and the USA, respectively,¹ although the incidence of these tumours appears to have gradually been increasing.² Approximately 85% of NETs arise from the gastrointestinal tract, 10% in the lungs, with the remainder in various organs such as the thymus.³ Thymic carcinoids have a distinct

Address for correspondence:

Angelos Kyriacou, Southmoor Road, Wythenshawe, Manchester, UK, M23 9LT, E-mail: angelos5@doctors.org.uk

Received: 21-07-2016, Accepted: 01-09-2016

expression pattern characterized by deregulation of many bio-functions including abnormal proliferation and differentiation signals, which may be involved in the development of NETs. Other abnormalities, like activation of neuropeptide signalling and inhibition of immune responses, may explain the hormonal disorders and immunity defects evident in ectopic adrenocorticotrophic hormone (ACTH) syndrome.⁴ Thymic carcinoids are rare tumours that exhibit a predilection for men, with a 3:1 male to female ratio.^{2,5} In 30% of cases these tumours are usually an incidental finding on routine radiography. The tumours often show cytological and architectural features of neuroendocrine differentiation, hence can be positive for CD56, neuron-specific enolase, chromogranin, somatostatin and synaptophysin.⁵

Most carcinoids are benign in behaviour, but thymic carcinoids display a much more aggressive phenotype and can be associated with ectopic ACTH syndrome, which in itself seems to be linked with poorer prognosis.⁶⁻⁷ It is unclear whether this latter correlation is due to metabolic complications secondary to Cushing's Syndrome (CS) or to inherently more aggressive tumour behaviour.

Urine steroid metabolomics make use of the differentiating expression of various steroid metabolites [Gas Chromatography Mass Spectrometry (GC/MS)] in order to try and distinguish between various conditions. It is an evolving field and has been applied for example to discriminate between benign and malignant adrenal tumours⁸ for early detection of recurrence of adrenocortical carcinoma⁹ and for the differential diagnosis of primary hyperaldosteronism.¹⁰ Here, we present a patient with ectopic CS where urine steroid metabolites were measured in an effort to determine whether there exists a specific metabolomic fingerprint for this rare condition.

CASE REPORT

A 51-year old lady was admitted with multiple cerebral, pulmonary and intra-abdominal abscesses. She was referred to the endocrine team because of newly-diagnosed type 2 Diabetes Mellitus. The combination of apparent immunosuppression, obesity (BMI 33.2 kg/m²; 18-25), diabetes mellitus (HbA1c 8.5%; $\leq 6.5\%$), hypertension (average blood pressure 154/90

mmHg), hypokalaemia (K^+ 2.9 mmol/L; 3.5-5.0), osteoporotic fractures and bilateral shoulder avascular necrosis (BSAN) led to a clinical diagnosis of CS. This was biochemically confirmed by non-suppressed cortisol in an overnight dexamethasone suppression test, midnight serum cortisol 4275 nmol/L (60-250), raised midnight salivary cortisol 716 nmol/L (5-46) and ACTH 639 ng/L (0-46). Urinary free cortisol (UFC) was elevated in excess of 75,000 nmol/24h (<165) on two occasions. Urinary steroids metabolites were markedly increased (Table 1) and the relevance of these metabolites to the steroid metabolic pathway can be seen in Figure 1. In particular, tetrahydrocortisol (THF) and tetrahydrocortisone (THE) were markedly raised at 219024 $\mu\text{g}/24\text{h}$ (435-1709) and 88848 $\mu\text{g}/24\text{h}$ (997-3870), respectively, with a (THF+5 α THF)/THE ratio also raised at 2.8 (≤ 1) (Table 1).

Given the markedly raised ACTH, cortisol and cortisol metabolites in association with hypokalaemia ectopic CS was more likely than Cushing's disease; indeed, given the computed tomography (CT) and positron emission tomography (PET) CT imaging appearances (Figure 2) of a thymic tumour and normal pituitary magnetic resonance imaging, a diagnosis of ectopic CS due to a thymic NET was reached without needing to embark on the high-dose dexamethasone suppression test, corticotrophin-releasing hormone stimulation test or bilateral inferior petrosal sinus sampling (IPSS). Urine 5-hydroxyindoleacetic acid (5HIAA) was marginally raised at 55 $\mu\text{mol}/24\text{h}$ (<45) and chromogranin A was normal at 52 pmol/L (<60). Octreotide scanning showed increased focal activity in the thymus. Multiple Endocrine Neoplasia type 1 (MEN1) was deemed to be quite unlikely given that the calcium was normal (2.36 mmol/L; 2.1-2.6) and there was no evidence of other NETs seen on abdominal CT imaging (which showed appearances of bilateral adrenal hyperplasia) and fasting gut peptides were within normal limits. Genetic testing was not required, especially given that our patient did not have any family history suggestive of MEN1.

Given that this woman presented with gross CS she required stabilization before surgical resection. This included the use of multiple and recurrent courses of potent antibiotic, antiviral and antifungal medications in order to treat the underlying infections. Metypalone was prescribed to treat hypercortisolaemia

Table 1. Urinary steroid metabolite levels in two separate collections of urine ($\mu\text{g}/24\text{h}$) done pre-operatively; before (testing 1) and after (testing 2) metyrapone use. Values obtained from the study of Brossaud *et al* for normal controls and patients with active Cushing's syndrome are also included.²⁰

	Steroid Metabolites			
	Testing 1 for case patient (pre-metyrapone)	Testing 2 for case patient (post-metyrapone)	Median values (95% CI) in normal controls ²⁰	Median values (95%CI) in active Cushing's disease ²⁰
Androgen Precursors ($\mu\text{g}/24\text{h}$)				
Androsterone	2734	1615		
Etiocholanolone	15835	4659		
Dehydroepiandrosterone	3033	589		
16 α -dehydroepiandrosterone	1243	55		
5-Pregnanetriol	3879	531		
5-Pregnanediol	3412	1783		
Pregnenien	6774	730		
Mineralocorticoids and Mineralocorticoid Precursors				
Tetrahydrodehydrocorticosterone	4213	1612		
5 α -Tetrahydrodehydrocorticosterone	1084	1120		
Tetrahydrocorticosterone	30600	9864		
5 α -Tetrahydrodehydrocorticosterone	13473	4323		
3 α 5 β -Tetrahydroaldosterone	0	2		
Tetrahydrodeoxycorticosterone	3830	2676		
5 α -Tetrahydrodeoxycorticosterone	371	205		
Glucocorticoid Precursors				
Pregnanediol	4983	1405		
3 α ,5 α , 17-Hydroxypregnenolone	250	47		
17-Hydroxypregnanolone	4588	1740		
Pregnanetriol	5344	2751		
Pregnanetriol-one	403	51		
Tetrahydrodeoxycortisol	56866	32292		
Glucocorticoids				
Cortisol	36716	20272	73 (25-135)	362 (180-2155)
6 β -OH-Cortisol	25285	17831		
Tetrahydrocortisol (THF)	219024	77524	2193 (809-411)	8637 (4561-37710)
5 α -Tetrahydrocortisol (5 α THF)	26484	4130		
α -Cortol	33272	34684	154 (48-313)	609 (226-3431)
β -Cortol	34829	9846	243 (75-650)	965 (328-6900)
11 β -OH-Androsterone	7774	1209		
11 β -OH-Etiocholanolone	32316	689		
Cortisone	1909	1380	115 (38-193)	301 (135-619)
Tetrahydrocortisone (THE)	88848	29393	2706 (1020-6124)	8561 (1742-23472)
A-cortolone	13775	13722	1036 (439-1956)	2712 (1222-5392)
B-cortolone	14042	4152	247 (81-570)	907 (385-3260)
11-Oxo-Etiocholanolone	7558	180		
18 OH Tetrahydrodeoxycorticosterone	114	57		
(THF+5 α THF)/THE	2.8	2.8		

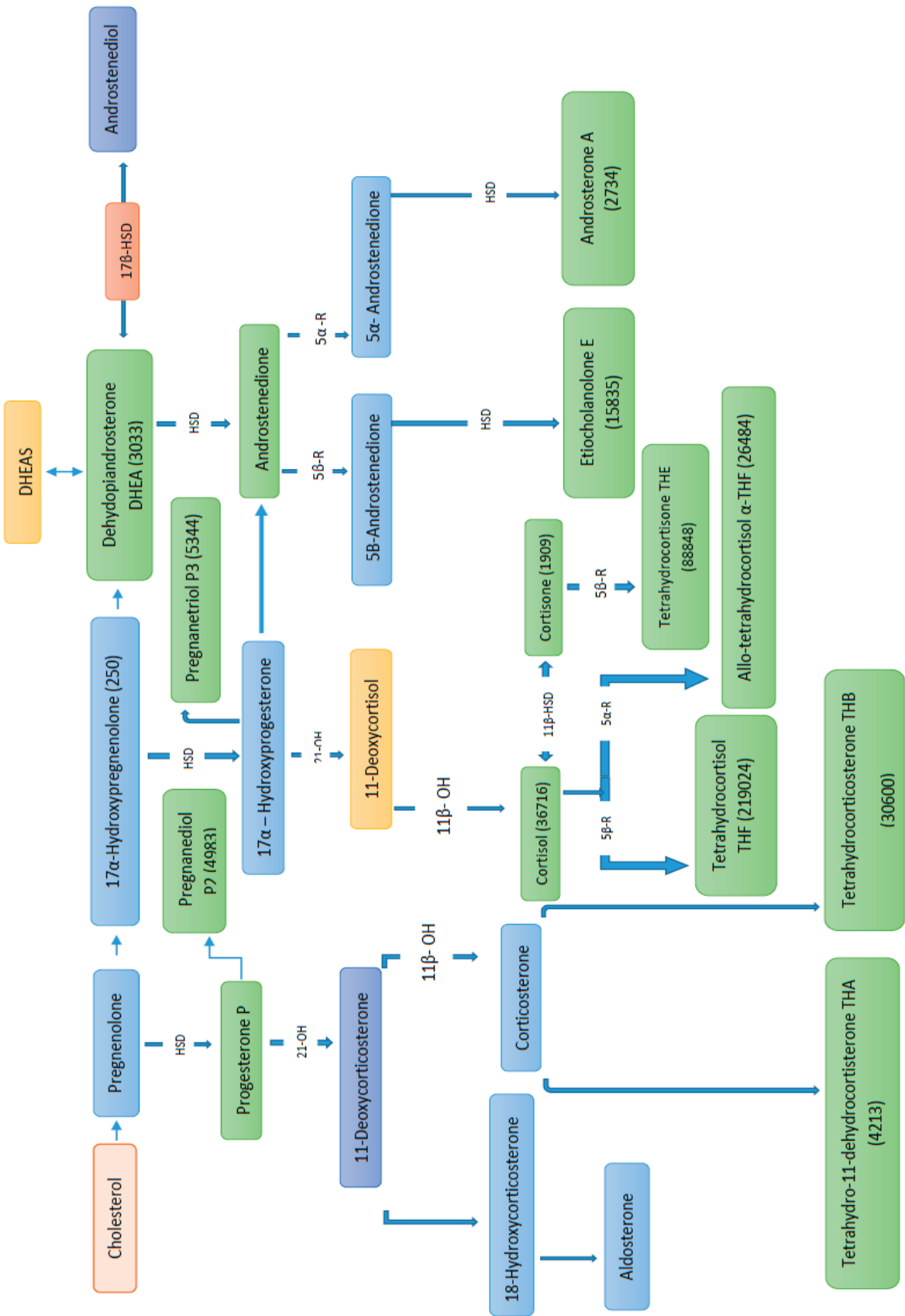


Figure 1. Steroid metabolic pathway with the values obtained from a 24 hour urine collection in our patient in brackets (units=μmol/24hrs). Please note that there is not one pathway that can include all steroid and urinary analytes described in Table 1. Also, this pathway illustrates that one steroid metabolite can often be the product of one or more steroids in the biochemical pathway.

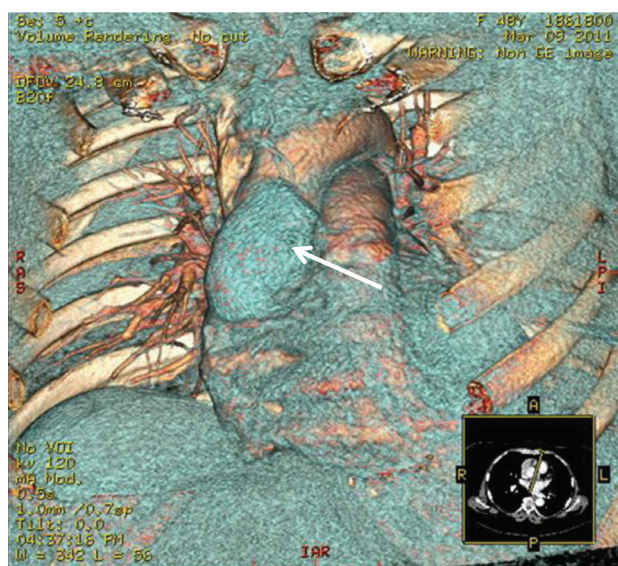

Figure 2. PET CT of the thorax indicating a large tumour in the anterior mediastinum (arrow) consistent with a thymic NET.

and reduce progression of CS complications; her urinary steroid metabolite profile post-metyrapone and pre-operatively is given in Table 1. Insulin was used to manage her hyperglycaemia. Potassium supplements, spironolactone and ramipril were given to achieve normotension and normokalaemia. Once the patient was rendered eucortisolaemic and haemodynamically and metabolically stable, she underwent thymectomy. Histology confirmed a paraganglioid variant of a thymic carcinoid tumour.

Post-operatively her 9am cortisol (off glucocorticoids) was below 50 nmol/L, which was indicative of disease remission. Thereafter, she displayed remarkable clinical and biochemical recovery, but poorly controlled diabetes, hypertension, obesity and BSAN continued to be active problems. She has now been in remission for the past five years.

DISCUSSION

We describe a case of ACTH-secreting thymic carcinoid that presented with florid clinical and biochemical features of CS. Profoundly elevated cortisol concentrations were observed in saliva, serum and urine, with loss of diurnal variation. Indeed, her UFC has possibly been the highest ever described. The markedly elevated total urinary excretion of cortisol in

CS secondary to ectopic ACTH production was previously described.^{11,12} In one case of ACTH-secreting CS, the UFC was as high as 45000 nmol/24h despite treatment with octreotide or ketoconazole.¹¹ In a review of all thymic carcinoids over a 25-year period from the National Institute of Health (NIH) in the US, the medium and highest UFC observed were 5,890 and 18,390 μ g/24hrs, respectively.¹³

Additionally, her detailed urine steroids analysis showed markedly high levels of cortisol and cortisone metabolites (THF and THE, respectively), which is pathognomonic for patients with CS.¹⁴ The analysis of urinary steroids metabolites was performed using GC/MS in the Centre for Endocrinology, Diabetes and Metabolism in Birmingham. The exact methodology has previously been described.⁸ The (THF+5 α THF)/THE ratio is used as an index of 11 β -hydroxysteroid dehydrogenase (11 β -HSD) activity and a ratio value of approximately 1 is considered as normal.¹⁵ 11 β -HSD involves an enzyme system that functions to catalyse the conversion of cortisol into cortisone;¹⁶⁻¹⁸ 11 β -HSD1 (relevant gene is HSD11B1 on chromosome = 1q32-q41) is present in the liver, testis, lung, adipose tissue and is a reduction enzyme that converts cortisone to cortisol; 11 β -HSD2 (relevant gene is HSD11B2 on chromosome 16q22) is found in the kidneys and placenta and is a dehydrogenase enzyme that converts cortisol to cortisone. The (THF+5 α THF)/THE ratio has previously been shown to be significantly increased in CS regardless of aetiology. However, it has been observed as being markedly higher in patients with ectopic ACTH syndrome as compared to pituitary-dependent CS (4.12 vs. 1.49, respectively; $p < 0.01$) and inversely correlated with serum potassium levels.¹⁴ In our case, the cortisol metabolites ratio was 2.8, which fell between the results mentioned above. To our knowledge, there are no definite cut-off values for (THF+5 α THF)/THE ratio that can differentiate between Cushing's disease and ectopic ACTH syndrome. There is a degree of overlap between these conditions, therefore the (THF+5 α THF)/THE ratio should be interpreted with caution. Indeed, it has been noted that a ratio between 1 and 3 may still be considered as normal. Therefore, based on this value only it is impossible to make a diagnosis of CS or indeed to ascertain its aetiology (Norman Taylor, personal communication). The quantity of cortisol excretion

and the rate of its excretion are very individual and vary between cases; the more florid CS is, the higher the UFC. Hence in our practice, we often interpret the (THF+5 α THF)/THE ratio along with the UFC result. The raised ratio of 5 β -THF to 5 α -THF (8.3 in this case) is of more clinical use and is usually indicative of CS (Norman Taylor, personal communication). Moreover, the (THF+5 α THF)/THE ratio has also been demonstrated to be clinically important in the diagnosis of hypertension caused by congenital absence of 11 β -HSD2 or inhibition of the enzyme after liquorice ingestion.¹⁹ With excessive cortisol secretion, 11 β -HSD2 can be saturated, causing an increase in the urine free cortisol to cortisone ratio and subsequently in the THF:THE ratio.

The inversion of the THF/THE ratio in our patient (Table 1) is likely due to a combination of increased expression of 11 β -HSD1 in adipose tissue and the florid hypercortisolaemia *per se*. Most of the glucocorticoid metabolites were profoundly decreased following treatment with metyrapone. It was surprising, however, that the inhibition of 11 β -hydroxylase did not increase upstream metabolites such as the androgens and tetrahydro-11-deoxycortisol (Table 1). The mechanism of this remains unclear.

Our case demonstrates not only that glucocorticoid metabolites are markedly increased in Ectopic CS but also that mineralocorticoid and sex hormone metabolites are significantly increased as well (Table 1). The various metabolites were increased to varying degrees in our own patient (Table 1). A recent study has examined urinary glucocorticoid metabolites to provide biomarkers for the classification of adrenal incidentalomas and has provided median values for 48 normal controls and 26 patients with active (pituitary) Cushing's disease.²⁰ With reference to these data, glucocorticoid metabolites were massively increased in our patient compared to normal control values (ranging from a ratio of 13 to 216 for α -cortolone and α -cortol, respectively) and increased even when compared with patients with active Cushing's disease (ranging from a ratio of 5 for α -cortolone and cortisone and 101 for α -cortol) (Table 2). The degree of increase in the various glucocorticoid metabolites in our patient followed the same order whether the values were compared to normal controls or to Cushing's disease and obeyed the following incremental

Table 2. Mean urinary glucocorticoid metabolite levels in index patient and comparison with mean values in normal controls and in active Cushing's disease. All measurements are in μ g/24h.

Urinary glucocorticoid metabolite	Baseline value in index patient	Ratio of baseline value in index patient over median value in normal population ²⁰	Ratio of baseline value in index patient over median value in active Cushing's disease ²⁰
Cortisol	36716	502	101
Cortisone	1909	17	6
THF	219024	100	25
THE	88848	33	10
THF/THE	0.03	0.25	2.47
α -cortol	33272	216	55
β -cortol	34829	143	36
A-cortolone	13775	13	5
B-cortolone	14042	57	15
Total	442415	65	19

sequence: α -cortolone, THE, β -cortolone, THF, β -cortol and α -cortol; these were lower than the comparative values for cortisol (Table 2). It should be emphasised that the analysis of urine steroids profile and serum cortisol were completed in different laboratories and as a result they have different units.

Approximately 200 cases of ACTH-secreting thymic carcinoid have been reported in the literature.^{6,11-13,21-23} Thymic carcinoids, which are associated with CS, occur over a wide age range of 4 to 64 years and show no gender predilection. The most common features of CS are manifestations of tumours producing ectopic ACTH, with hypertension, oedema, severe hypokalemia and myasthenia being more common in ectopic ACTH-producing tumours than in Cushing's disease.^{23,24} Incomplete processing of ACTH precursors causing higher levels of pro-opiomelanocortin (POMC) have been described with ectopic ACTH, which has been proposed as a way of differentiating it from Cushing's disease.²⁵ We have previously shown that cross-reactivity of POMC in currently available 'ACTH' immunoassays varied from a mean of 1.6-4.7% which caused a large percentage increase in measured ACTH of up to 261%,²⁶ albeit we have not measured POMC in this particular patient.

Our patient experienced various bacterial, fungal and viral infections and septicaemia that were disseminated in time and site and proved difficult to treat despite use of strong antibiotics, antiviral and antifungal agents and input from an on-site infectious disease team. It is possible that the accompanying hyperglycaemia has contributed to this phenomenon. Our case illustrates that hypercortisolaemia should be part of the differential diagnosis of acquired immunosuppression. Indeed, when 54 patients with ectopic ACTH production, but without lung cancer, were examined, it was shown that the more severe the hypercortisolaemia the more likely is the presence of severe infections (including sepsis); often these infections behaved atypically with no/mild fever and normal/near-normal white cell counts.²⁷

Once the tumour is successfully removed, lifelong surveillance involves similar investigations to those used for monitoring patients with CS i.e. UFC, ODST and/or salivary cortisol. Primary thymic NETs have a poor prognosis. This is due to the aggressive nature of the tumour with a high post-operative recurrence rate. Low-grade thymic carcinoids present a 5-year survival of 50% and 10-year survival of 9%, whereas high-grade thymic carcinoids have a 5-year survival of 0%.⁵ Patients with tumour recurrence are likely to develop CS again and an important part of their management is controlling hypercortisolism, either with ketoconazole and/or metyrapone or bilateral adrenalectomy.²⁰

CONCLUSION

This case demonstrates the biochemistry that one may expect to see with florid ectopic CS. It also emphasizes that one steroid metabolite can be the product of one or more steroids in the biochemical pathway, as was noted with various mineralocorticoid and sex hormone steroid metabolites that were raised in our case. Furthermore, it is conceivable that that urinary steroid metabolomics could be increasingly used in the near future for diagnosing ectopic CS as it seems to be associated with much higher urinary glucocorticoid metabolites than CS; similarly such metabolites may be useful for monitoring disease recurrence in ectopic CS.

DECLARATION OF COMPETING INTERESTS

All authors declare no competing interests.

FUNDING

No funding was obtained for this study.

ETHICAL APPROVAL

No ethical approval was required for this study. Written informed consent was obtained from the aforementioned patient.

ACKNOWLEDGMENTS

We would like to thank Dr. Tim Cooksley (Department of Acute Medicine, UHSM) and Dr. Richard Sawyer (Department of Radiology, UHSM) for their support in the management of this patient, Prof. Brian Keevil (Biochemistry Laboratory, UHSM) for cortisol measurement as well as Dr. Norman Taylor (Department of Biochemistry, King's College Hospital) and Dr. Angela Taylor (the Centre for Endocrinology, Diabetes and Metabolism in Birmingham) for their general advice on urinary steroid profiling.

REFERENCES

1. Hauso O, Gustafsson BI, Kidd M, et al, 2008 Neuroendocrine tumor epidemiology: contrasting Norway and North America. *Cancer* 113: 2655-2664.
2. Modlin IM, Oberg K, Chung DC, et al, 2008 Gastroenteropancreatic neuroendocrine tumours. *Lancet Oncol* 9: 61-72.
3. Barakat MT, Meeran K, Bloom SR, 2004 Neuroendocrine tumours. *Endocr Relat Cancer* 11: 1-18.
4. Bi Y, Liu R, Ye L, et al, 2009. Gene expression profiles of thymic neuroendocrine tumors (carcinoids) with ectopic ACTH syndrome reveal novel molecular mechanism. *Endocr Relat Cancer* 16: 1273-1282.
5. Öberg K, Hellman P, Ferolla P, 2012 Neuroendocrine bronchial and thymic tumors: ESMO Clinical Practice Guidelines for diagnosis, treatment and follow-up. *Ann Oncol* 23: 120-123.
6. Duh QY, Hybarger CP, Geist R, et al, 1987 Carcinoids associated with multiple endocrine neoplasia syndromes. *Am J Surg* 154: 142-148.
7. Kondo K, Monden Y, 2003 Lymphogenous and hematogenous metastasis of thymic epithelial tumors. *Ann*

- Thorac Surg 76: 1859-1864.
8. Arlt W, Biehl M, Taylor AE, et al, 2011 Urine steroid metabolomics as a biomarker tool for detecting malignancy in adrenal tumors. *J Clin Endocrinol Metab* 96: 3775-3784.
 9. Chortis V, Bancos I, Sitch AJ, et al, 2016 Urine steroid metabolomics is a highly sensitive tool for post-operative recurrence detection in adrenocortical carcinoma. European conference of endocrinology. *Endocrine abstracts*. <http://www.endocrine-abstracts.org/ea/0041/ea0041OC1.4.htm>.
 10. Lang K, Beuschlein F, Biehl M, et al, 2015 Urine steroid metabolomics as a diagnostic tool in primary aldosteronism. *Endocrine abstracts*. <http://www.endocrine-abstracts.org/ea/0038/ea0038oc1.6.htm>
 11. Jansson JO, Svensson J, Bengtsson BA, et al, 1998 Acromegaly and Cushing's syndrome due to ectopic production of GHRH and ACTH by a thymic carcinoid tumour: in vitro responses to GHRH and GHRP-6. *Clin Endocrinol* 48: 243-250.
 12. Laatz JM de, Pieterman CR, van den Broek MF, et al, 2014 Natural Course and Survival of Neuroendocrine Tumors of Thymus and Lung in MEN1 Patients. *J Clin Endocrinol Metab* 99: 3325-3333.
 13. Neary NM, Lopez-Chavez A, Abel BS, et al, 2012 Neuroendocrine ACTH-producing tumor of the thymus-experience with 12 patients over 25 years. *J Clin Endocrinol Metab* 97: 2223-2230.
 14. Stewart PM, Walker BR, Holder G, et al, 1995 11 beta-Hydroxysteroid dehydrogenase activity in Cushing's syndrome: explaining the mineralocorticoid excess state of the ectopic adrenocorticotropin syndrome. *J Clin Endocrinol Metab* 80: 3617-3620.
 15. Wolthers BG, Kraan GP, 1999 Clinical applications of gas chromatography and gas chromatography-mass spectrometry of steroids. *J Chromatogr A* 843: 247-274.
 16. Palermo M, Shackleton CH, Mantero F, et al, 1996 Urinary free cortisone and the assessment of 11 beta-hydroxysteroid dehydrogenase activity in man. *Clin Endocrinol* 45: 605-611.
 17. Fong BM-W, Tam S, Leung KS-Y, 2010. Improved liquid chromatography-tandem mass spectrometry method in clinical utility for the diagnosis of Cushing's syndrome. *Anal Bioanal Chem* 396: 783-790.
 18. Stiefel P, García-Morillo JS, Jimenez L, et al, 2002 Role of ketoconazole treatment in urinary-free cortisol-to-cortisone and tetrahydrocortisol-to-tetrahydrocortisone ratios in nonectopic Cushing's syndrome. *Endocrine* 18: 279-284.
 19. Turpeinen U, Markkanen H, Sane T, et al, 2006 Determination of free tetrahydrocortisol and tetrahydrocortisone ratio in urine by liquid chromatography-tandem mass spectrometry. *Scand J Clin Lab Invest* 66: 147-159.
 20. Brossard J, Ducint D, Corcuff J-B, 2016 Urinary glucocorticoid metabolites: biomarkers to classify adrenal incidentalomas? *Clin Endocrinol* 84: 236-243.
 21. Valeriani M, Agolli L, Falco T, et al, 2012 A case report of metastatic atypical thymic carcinoid with ectopic ACTH production: locoregional control after adaptive radiation treatment. *Tumori* 98: 172-175.
 22. Modlin IM, Sandor A, 1997 An analysis of 8305 cases of carcinoid tumors. *Cancer* 79: 813-829.
 23. McEvoy MP, Rich BS, New M, et al, 2011 Thymic carcinoid presenting with Cushing's syndrome in a 17-year-old boy: a case report and review of the literature. *J Clin Oncol* 29: 716-718.
 24. Isidori AM, Kaltsas GA, Pozza C, et al, 2006 The ectopic adrenocorticotropin syndrome: clinical features, diagnosis, management, and long-term follow-up. *J Clin Endocrinol Metab* 91: 371-377.
 25. Page-Wilson G, Freda PU, Jacobs TP, et al, 2014 Clinical Utility of Plasma POMC and AgRP Measurements in the Differential Diagnosis of ACTH-Dependent Cushing's Syndrome. *J Clin Endocrinol Metab* 99: 1838-1845.
 26. Monaghan PJ, Kyriacou A, Sturgeon C, et al, 2016 Proopiomelanocortin interference in the measurement of adrenocorticotrophic hormone: a United Kingdom National External Quality Assessment Service study. *Clin Endocrinol (Oxf)* 85: 569-574.
 27. Ilias I, Torpy DJ, Pacak K, et al, 2005 Cushing's syndrome due to ectopic corticotropin secretion: twenty years' experience at the National Institutes of Health. *J Clin Endocrinol Metab* 90: 4955-4962.